

## Brief Report

# The treatment effect of the burn wound healing by electrolytic-reduction ion water lotion

Tetsuo Shu<sup>1,\*</sup>, Masahiro Okajima<sup>2</sup>, Ken-ichi Shimokawa<sup>2</sup>, Fumiyoshi Ishii<sup>2,\*\*</sup>

<sup>1</sup> Daikanyama Clinic of Cosmetic Surgery, Shibuyaku, Tokyo, Japan;

<sup>2</sup> Department of Pharmaceutical Sciences, Meiji Pharmaceutical University, Tokyo, Japan.

### Summary

A 2-year-and-4-month-old girl suffered a burn to the neck due to boiling water. She was examined at another hospital, and recommended to undergo dermatoplasty. Thirteen days after injury, she consulted our hospital. A wide skin defect was observed around the neck, and a third-degree burn was diagnosed. Conservative treatment using electrolytic-reduction ion water (ERI) lotion, antibiotics/steroid combination ointment, and vitamin A/E ointment was performed without dermatoplasty. Treatment of the burn was started with the application of ERI lotion, antibiotics/steroid combination ointment, and vitamin A/E ointment to the wound 3 times a day combined with wrap therapy. The lysis of necrotic tissue and granulation began 1 week after the beginning of treatment. After 2 weeks, the necrosed skin had completely lysed, satisfactory granulation tissue began to form and blood supply improved. Regeneration of the skin was noted at 1-3 months after the beginning of treatment. Complete epithelialization was observed after 4 months, but hypertrophic cicatrization and pigmentation began to occur. After 26 months, capillary growth was observed, cicatrix became inconspicuous, pigmentation disappeared, and the burn almost completely healed. In conclusion, in this patient, the process of tissue repair after burn injury progressed smoothly, and healing was achieved without leaving hypertrophic cicatrix, keloid scar, or pigmentation. Our experience suggested that even third-degree burns can be treated using only external therapy with ERI lotion, antibiotics/steroid combination ointment, and vitamin A/E ointment without dermatoplasty.

**Keywords:** Electrolytic-reduction ion water, burn wound, moist wound healing, conservative treatment, wrap therapy

### 1. Introduction

There are still many instances of burn injury caused by boiling water (1). Particularly, children with immature skin tend to suffer deeper and severer burns compared with adults. On treating third-degree burns, mesh skin grafting and patch dermatoplasty are often performed after debridement to prevent contracture of the injury site and shorten the treatment period. Recently, improvements in the properties of the skin transplantation site and shortening of the treatment period have been reported

\* Dr. Tetsuo Shu passed away.

\*\*Address correspondence to:

Dr. Fumiyoshi Ishii, Department of Pharmaceutical Sciences, Meiji Pharmaceutical University, 2-522-1 Noshio, Kiyose, Tokyo 204-8588, Japan.  
e-mail: fishii@my-pharm.ac.jp

in many patients by applying Fiblast<sup>®</sup> Spray (Kaken Pharmaceutical Co., Ltd.) to the graft surface (2-5). However, it has also been recognized that hypertrophic cicatrix or keloid is likely to be suppressed at a mild level even in deep burns by appropriate treatment from an early stage (6).

We have performed some studies on the characteristics of ERI (7-9). ERI is water containing a large amount of electrons through the electrolysis of natural water, followed by electric current/pressure application using a special diaphragm system. ERI shows cleansing, deodorizing, antimicrobial, and anti-dust effects because dirt and bacteria, as the causes of odor, are detached and removed by its specific alkaline property and negatively charged ions (7). This water also has rust-preventing and anti-septic effects. In addition, stable emulsions could be prepared by the

emulsification of various types of oil using ERI alone without emulsifiers, showing its emulsifying effect (8). Taking advantage of these properties, ERI is widely used at present as a cleansing agent incorporated in various industrial products.

We previously prepared magnesium aluminum silicate (Smectone<sup>®</sup>) gels using ERI as a dispersal medium for medical drugs, and evaluated their physicochemical properties (10,11). As a result, the use of ERI, compared with purified water, facilitated the preparation of drug delivery system (DDS) drugs with the maintenance of the gel state. These results showed that the use of gels with functions maintained using the specific properties of ERI is useful for preparing percutaneously absorbed drugs such as sustained-release preparations.

This report presents a girl with a third-degree burn that could be treated satisfactorily by conservative therapy using ERI lotion, antibiotics/steroid combination ointment, and vitamin A/E ointment without dermatoplasty, which was rejected by her parents.

## 2. Materials and Methods

### 2.1. Materials

As ERI, S-100<sup>®</sup> (A. I. System Product Co., Japan) was used. ERI lotion containing 2% vitamin C was from A. I. System Product Co., Japan. For the antibiotics/steroid combination ointment, Hysetin-P<sup>®</sup> (chloramphenicol, fradiomycin sulfate, and prednisolone combination) was from Fuji Pharmaceutical Industry Co., Ltd., Japan. The vitamin A/E ointment, Juvela<sup>®</sup> (vitamin A and tocopherol combination), was from Eisai Co., Ltd., Japan. All reagents were of special grade.

### 2.2. Methods

The burn was treated by the application of ERI lotion, antibiotics/steroid combination ointment (Hysetin-P<sup>®</sup>), and vitamin A/E ointment (Juvela<sup>®</sup>) to the injury site 3 times a day combined with wrap therapy, *i.e.*, wrapping the injury site with a thin plastic film to prevent drying (12).

## 3. Results and Discussion

The patient was a 2-year-and-4-month-old girl. After she suffered a burn to the neck due to boiling water, she was examined at another hospital, was recommended to undergo dermatoplasty, and consulted our hospital 13 days after injury. A wide skin defect was observed around the right side of the neck, and a third-degree burn was diagnosed.

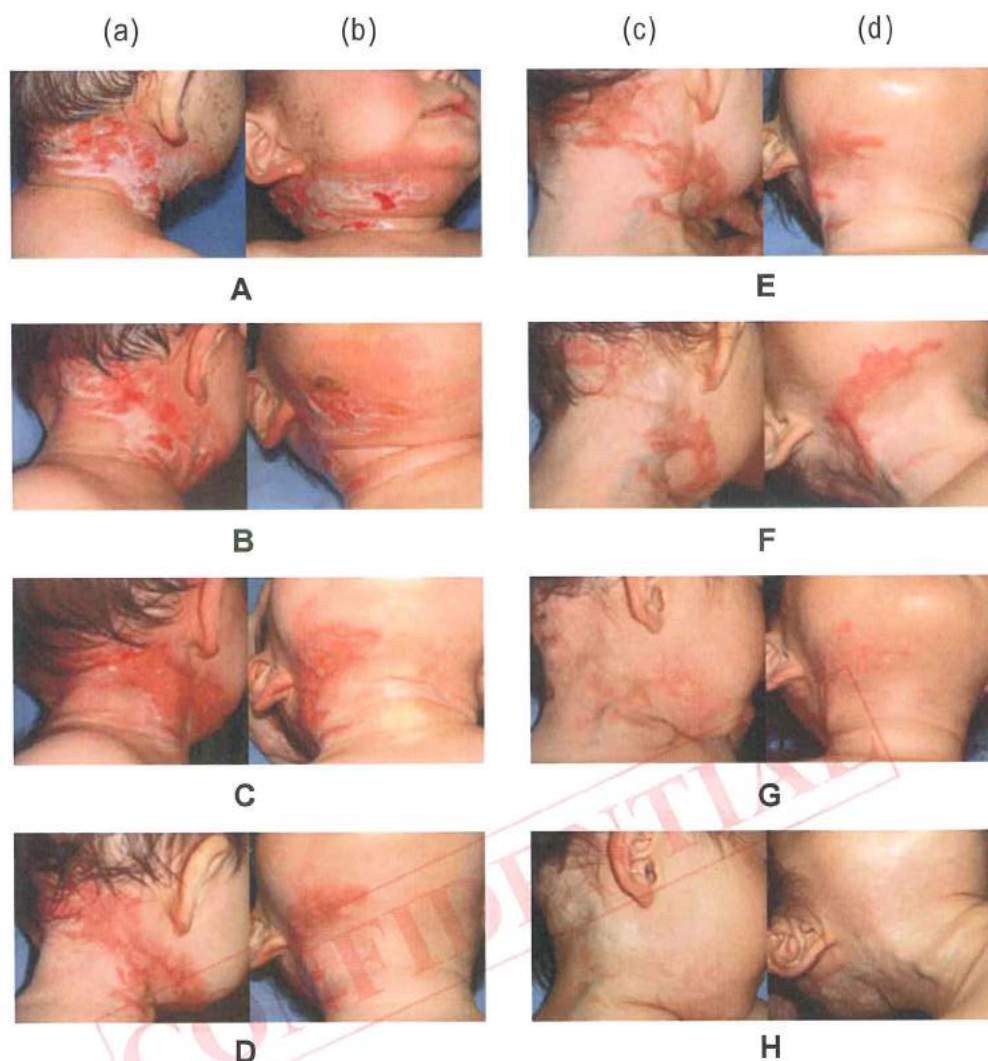
Because of the strong wish of her parents to avoid dermatoplasty, treatment was started by the application of ERI lotion, antibiotics/steroid combination ointment, and vitamin A/E ointment to the wound 3 times a day

combined with wrap therapy. Figure 1A shows the state of the third-degree burn soon after the beginning of treatment. Figure 1B shows the state after 1 week, when the lysis of necrotic tissue and granulation formation started. Two weeks after the beginning of treatment, the necrosed skin had completely lysed, satisfactory granulation tissue formation was observed, and the blood supply improved. After 3 weeks, the concavity gradually began to flatten. Figures 1C-1E show the states 1-3 months after the beginning of treatment. Skin regeneration was noted, epithelialization progressed, and the area of the skin defect began to decrease. Figure 1F shows the state after 4 months, when epithelialization had completed, but hypertrophic cicatrix and pigmentation began to appear. After 6-9 months, the area of hypertrophic cicatrix gradually decreased, being replaced by normal skin. Figure 1G shows the state after 13 months. Capillary vessel proliferation was noted, cicatrix became inconspicuous, and pigmentation was resolved, showing satisfactory healing. Figure 1H shows the state after 26 months. Normal skin was restored in the area of cicatrix, and no functional disorder remained.

Usually, the treatment of burns often requires surgical skin grafting depending on the depth of the wound in addition to conventional external drug treatment. In the present patient, to comply with the strong wish of her parents for outpatient treatment without skin grafting, we performed conservative treatment using ERI lotion containing vitamin C, antibiotics/steroid combination ointment, and vitamin A/E ointment. Vitamin C was added to the ERI lotion in the process of its manufacturing, because vitamin C has been reported to promote wound healing (13). In this patient, the processes of tissue repair in the healing of the burn, *i.e.*, inflammation, granulation, and reconstruction, progressed smoothly, and cure could be achieved without leaving hypertrophic cicatrix, keloid scar, or pigmentation. This case is considered to demonstrate that third-degree burns can be treated simply by external treatment using ERI lotion, antibiotics/steroid combination ointment, and vitamin A/E ointment.

## References

1. Hettiaratchy S, Dziewulski P. ABC of burns: pathophysiology and types of burns. *British Med J.* 2004; 328:1427-1429.
2. Akita S, Akino K, Imaizumi T, Hirano A. A basic fibroblast growth factor improved the quality of skin grafting in burn patients. *Burn.* 2005; 31:855-858.
3. Akita S, Akino K, Imaizumi T, Tanaka R, Anraku K, Yano H, Hirano A. The quality of pediatric burn scars is improved by early administration of basic fibroblast growth factor. *J Burn Care Res.* 2006; 27:333-338.
4. Akita S, Akino K, Imaizumi T, Hirano A. Basic fibroblast growth factor accelerates and improves second-degree burn wound healing. *Wound Repair Regen.* 2008; 16:635-641.



**Figure 1.** A case of treatment of a burn wound of the right neck region with ERI lotion, antibiotic/steroid combination ointment, and vitamin A/E ointment employing wrap therapy. (a) The rear right side of the neck region, (b) the front right side of the neck region. The photographs (c) and (d) are from the same patient. (A) Before treatment. (B) 1 week after treatment (C) 1 month after treatment (D) 2 months after treatment. (E) 3 months after treatment. (F) 4 months after treatment. (G) 15 months after treatment. (H) 26 months after treatment.

5. Ono I, Akasaka Y, Kikuchi R, Sakemoto A, Kamiya T, Yamashita T, Jimbow K. Basic fibroblast growth factor reduces scar formation in acute incisional wounds. *Wound Rep Reg.* 2007; 15:617-623.
6. Ono I. The molecular biological aspect of wound healing and treatments of chronic wound applying its concept. *J Clinical Surgery.* 2007; 62:1481-1495.
7. Okajima M. Abstract of Japanese society for applied research in negative ion. 2002.
8. Konomatu A, Sugibayashi K, Okajima M, Ishii F. Preparation and stability of surfactant free emulsions using electrolyzed deoxidized and ionized water. *Material Tech.* 2003; 21:273-285.
9. Kitamura T, Koike M, Todo H, Okajima M, Ishii F, Sugibayashi K. Preparation of surfactant-free emulsions using electrolyzed water and its regulation effect on the skin permeation of compounds. *Nippon Koshohin Gakkaishi.* 2008; 32:1-9.
10. Takigawa T, Okajima M, Shimokawa K, Ishii F. Physicochemical properties of magnesium aluminum silicates (smectites<sup>®</sup>) gels prepared by electrolytic-reduction ion water (1): rheological properties. *Mater Technol.* 2008; 26:50-54.
11. Okajima M, Shimokawa K, Ishii F. Physicochemical properties of magnesium aluminum silicate (smectone<sup>®</sup>) gels prepared using electrolytic-reduction ion water (2): effects of various salts on the phase diagram. *Colloids Surf B Biointerfaces.* 2009; 72:284-288.
12. Natui M. Therapeutic management of problematic superficial wounds: a patients-centered approach. *J Wound Care.* 2003; 12:63-66.
13. Collins N. The facts about vitamin C and wound healing. *Ostomy Wound Manage.* 2009; 55:8-9.
14. Treharne LJ, Kay AR. The initial management of acute burns. *J R Army Med Corps.* 2001; 147:198-205.
15. Takahashi J, Yokota O, Fujisawa Y, Sasaki K, Ishizu H, Aoki T, Okawa M. An evaluation of polyvinylidene film dressing for treatment of pressure ulcers in older people. *J Wound Care.* 2006; 15:449-454.

(Received October 25, 2009; Accepted December 18, 2009)