

## Original Article

# The healing effect of electrolytic-reduction ion water on burn wounds

Masahiro Okajima, Ken-ichi Shimokawa, Fumiyoshi Ishii\*

Department of Pharmaceutical Sciences, Meiji Pharmaceutical University, Tokyo, Japan.

### Summary

We prepared a lotion using electrolytic-reduction ion water (ERI), and evaluated the healing effects of this lotion (ERI lotion) on burn wounds. Third degree burn wounds were induced in the mouse dorsal skin, and ERI lotion or physiological salt (PS) lotion was applied to the wounds from immediately after injury [ERI (+) group and ERI (-) group as a control group, respectively]. The burn wound area was measured, and its serial changes were evaluated. In addition, histological examination of the burn wound site (on day 3) was performed. Comparison of the ERI (+) and (-) groups showed a significant reduction in the burn wound area in the former. Histological examination confirmed many interstitial spaces, blood vessels, and lymphatic vessels in the subcutaneous tissue in the ERI (-) compared with the ERI (+) group. These results suggest the promotion of burn wound healing by ERI lotion.

**Keywords:** Electrolytic-reduction ion water, burn wound healing, burn wound, edema, subcutaneous tissue

### 1. Introduction

Wound healing is a phenomenon in which regeneration or wound repair reactions occur in tissues and cells that have become defective due to tissue injury such as by trauma. The types of trauma include incised, contused, or stab wounds, burns, and chemical injuries. The series of biological reactions by which the human body attempts to repair and reconstruct tissues themselves and functions that have been lost by the above mechanisms is called wound healing (1). Among the types of trauma, burns are skin injuries caused by heat, classified according to their depth of the burn degree into: First-degree, injury involving only the skin surface; second-degree, injury that also involves the dermis and is often accompanied by edema; and third-degree, injury involving the dermis and subcutaneous tissue and often resulting in scar formation after healing; fourth-degree, injury involving the deep structures, such as muscle,

tendon, bone, *etc.* (2). For second and third degree burns, the main treatment method was conventionally local therapy with drugs (such as disinfectants and ointments containing steroids or antibiotics), but has been gradually changed to sealing therapy with various wound dressings (such as polyurethane film, hydrocolloid, polyether form, and hydro-gel, alginate dressing, or hydro-polymer) to promote biological repair mechanisms (3,4). These drugs for local therapy and wound dressings play important roles such as the promotion of epithelialization, prevention of infection, and reduction of pain in injured areas. Recently, basic fibroblast growth factor (bFGF) preparations have also been clinically applied, shortening the burn wound healing period (5-8).

We have performed some studies on the characteristics of ERI (9-11). ERI is water containing a large amount of electrons through the electrolysis of natural water, followed by electric current/pressure application using a special diaphragm system. ERI shows cleaning, deodorant, antimicrobial, and antiodor effects because dirt and bacteria, as the causes of odor, are detached and removed by its specific alkaline property and negatively charged ions (9). This water also has rust-preventing and anti-septic effects. In addition, stable emulsions could be prepared by

\*Address correspondence to:

Dr. Fumiyoshi Ishii, Department of Pharmaceutical Sciences, Meiji Pharmaceutical University, 2-522-1 Noshio, Kiyose, Tokyo 204-8588, Japan.  
e-mail: fishii@my-pharm.ac.jp

emulsification of various types of oil using ERI alone without using emulsifiers, showing its emulsifying effect (10). Taking advantages of these properties, ERI is widely used at present as a cleaning agent incorporated in various industrial products.

We previously prepared magnesium aluminum silicate (Smectone<sup>®</sup>) gels using ERI as a dispersal medium for medical drugs, and evaluated their physiochemical properties (12,13). As a result, the use of ERI compared with purified water facilitated the preparation of drug delivery system (DDS) drugs with the maintenance of the gel state. These results showed that the use of gels with functions being maintained using the specific properties of ERI is useful for preparing percutaneously absorbed drugs such as sustained-release preparations.

In this study, to facilitate the application of ERI as a component of medical drugs, we evaluated the healing effects of this water on burn wounds.

## 2. Materials and Methods

### 2.1. Animals

The present study was approved by the Institutional Review Board, Meiji Pharmaceutical University, using 14 male ddY mice aged 7 weeks (Sankyo Labo Service Co., Japan).

### 2.2. Materials and reagents

As ERI, S-100<sup>®</sup> (A.I. System Product Co., Japan) was used. All reagents were of special grade.

### 2.3. Preparation of ERI and PS lotions

For the preparation of ERI and PS lotions, sodium carboxymethylcellulose (cmc-Na) (Kanto Chemical Co., Inc., Tokyo, Japan) was added to each dispersal medium (ERI or PS) to adjust the final concentration to 7%.

### 2.4. Induction of burns

Under anesthesia induced by the intraperitoneal injection (0.05 mg/g, *i.p.*) of pentobarbital sodium (Nacalai Tesque, Inc., Kyoto, Japan), the back of mice after 24 h fasting was shaved using electric clippers, and hair was removed using a depilatory cream based on the reports by Papp *et al.* and Kaneko *et al.* (14,15). Third degree burn was induced by applying the tip of an electric soldering iron (HAKKO FX-951, Hakko Co., Osaka, Japan) at 300°C to the mouse back for 5 seconds. The side of the tip of the soldering iron was evenly applied so that the pressure at the time of burn induction was constant. To avoid variations between experiments, the same researcher produced all burns.

### 2.5. Measurement of the burn wound area

Burn wounds were induced in 12 mice, and the mice were randomly divided into two groups (6 mice each) undergoing the application of ERI lotion [ERI (+) group] or PS lotion [ERI (-) group]. Immediately after wound induction (day 0), the wound was photographed using a digital camera (EXILIM EX-Z4, Casio Computer Co., Ltd., Tokyo, Japan). After wounding, ERI or PS lotion was applied 3 times daily in each group, and the wound was photographed. Based on image data obtained using the digital camera, the wound area was measured using Image J software (Bioarts, Co., Ltd., Fukuoka, Japan). The wound area on each measurement day as a percentage of that on the day of wound induction was calculated, and the healing effects of ERI lotion were evaluated.

### 2.6. Histological examination

In 2 mice, burn wounds on the back were induced by a method similar to the above using an electric soldering iron. One mouse was topically treated with ERI lotion and the other with PS lotion 3 times daily. On day 3 after wound induction, the mice were sacrificed by lethal inhalation anesthesia with diethyl ether. The skin including tissue around the wound was resected and immersed in 20% neutral buffered formalin solution for pathological examination (Kanto Chemical Co., Inc., Tokyo, Japan), and paraffin sections (4  $\mu$ m in thickness) were prepared and stained with hematoxylin-eosin (HE) to obtain histological cross-sectional specimens of the skin. Subsequently, each specimen was photographed using a digital camera and histologically observed. The preparation and evaluation of histological specimens were outsourced to the Hist Science Laboratory Co., Ltd., Tokyo, Japan.

### 2.7. Observation of blood vessels near the wound

The 2 mice used for histological evaluation were sacrificed on day 3 after burn wound induction. The dorsal skin was resected, and the state of the capillaries in subcutaneous tissue was observed.

### 2.8. Statistical analysis

For each measurement item, the mean and standard deviation of data in each group were calculated. Statistical analysis was performed by employing Wilcoxon's rank sum test, and  $p < 0.05$  was considered significant.

## 3. Results

In this study, for the application of ERI to medical drugs, we evaluated the healing effects of ERI lotion

on burn wounds. As general parameters for the evaluation of wound healing, days until the completion of epithelialization and the wound area are used. Therefore, in this experiment, third degree burn wounds were induced on the backs of mice, and the wound area was serially measured and compared with that in the

controls treated with PS lotion.

3.1. Time-course changes in the wound area

The wound area on each measurement day as a percentage of that on the day of burn wound induction was calculated and compared between the groups (Figure 1). On day 1, the wound area did not differ between the two groups. Wound healing was more advanced in the ERI (+) group compared with the ERI (-) group from day 2, and a definite difference was observed between the two groups from day 3. The wound healing area did not markedly vary among the mice in the ERI (+) group, consistently showing a decrease. In the ERI (-) group, the wound healing area slightly varied on day 6 or more. Wilcoxon's rank sum test of measurement data showed no significant difference on day 1 but significant differences (\*) from day 2.

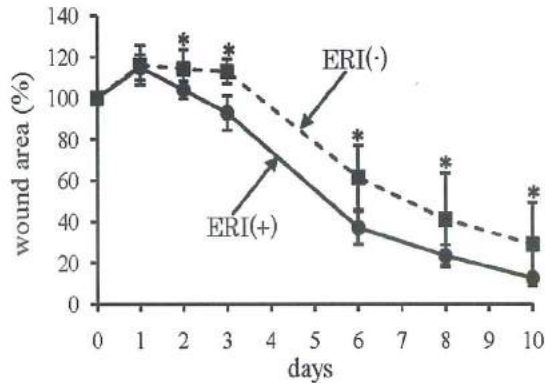


Figure 1. Percentage changes in the wound area after burn wound induction. Serial changes in the wound area on each measurement day as a percentage of that on the day of wound induction (day 0). Data are shown as the mean value ± standard errors. ERI (+): ERI lotion application (solid line). ERI (-): PS lotion application (dashed line). In each group, n = 6 (\*: p < 0.05).

3.2. Changes in healing after burn wound induction

After burn wound induction, ERI or PS lotion was applied 3 times daily in each group, and the burn wound site was photographed on days 0, 3, 6, 8, 10, and 17 and compared between the ERI (+) and (-) groups (Figure 2). As a result, definite healing effects were observed

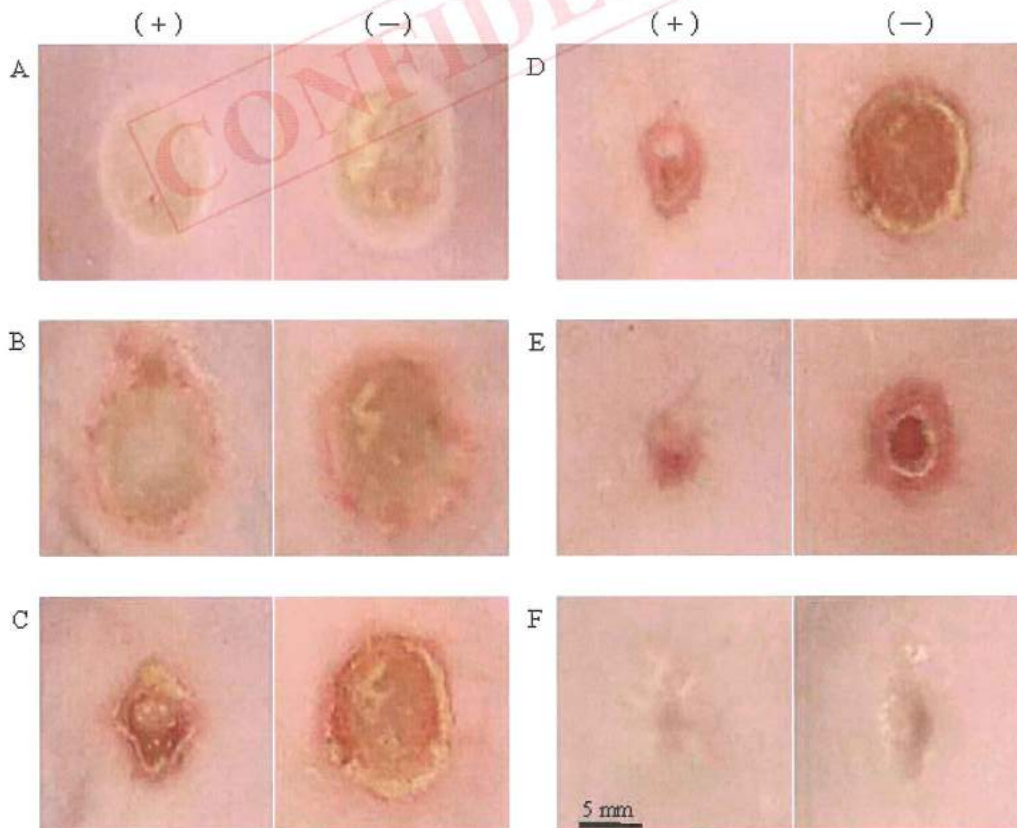


Figure 2. Changes in the healing process after burn wound induction. A: 0 day, B: 3 days, C: 6 days, D: 8 days, E: 10 days, F: 17 days. (+): ERI lotion application, (-): PS lotion application. The central area indicates the wound site.

in the ERI (+) group compared with the ERI (-) group from day 6. On day 10, almost complete healing was observed in the ERI (+) group. A comparison of scars after complete healing (day 17) revealed milder skin depression and less noticeable scars in the ERI (+) than in the ERI (-) group.

### 3.3. Microscopy inside burn wounds

Cross-sections ( $\times 20$ ) of the wound site after HE staining on day 3 are shown in Figure 3. Here, the specimen after treatment with ERI lotion (Figure 3A) is indicated by (+) and that after treatment with PS lotion (Figure 3B) by (-), and a specimen of a normal area without a burn wound as a control (Figure 3C) is also shown. The subcutaneous tissue (SC) and the cutaneous muscle (CM) represent subcutaneous tissue and the cutaneous muscle, respectively.

In the ERI (-) specimen, there were many parts not stained with HE (closed arrowhead) in the SC (Figure 3B), indicating the presence of many interstitial spaces, blood vessels, and lymphatic vessels. In the ERI (+) specimen, the SC was densely stained, suggesting less extensive wounding compared with the ERI (-) specimen

(Figure 3A). However, the ERI (+) specimen showed more unstained parts (open arrowhead) in the CM than the ERI (-) specimen and wide interstitial spaces in the CM, suggesting muscle fiber atrophy (Figure 3A).

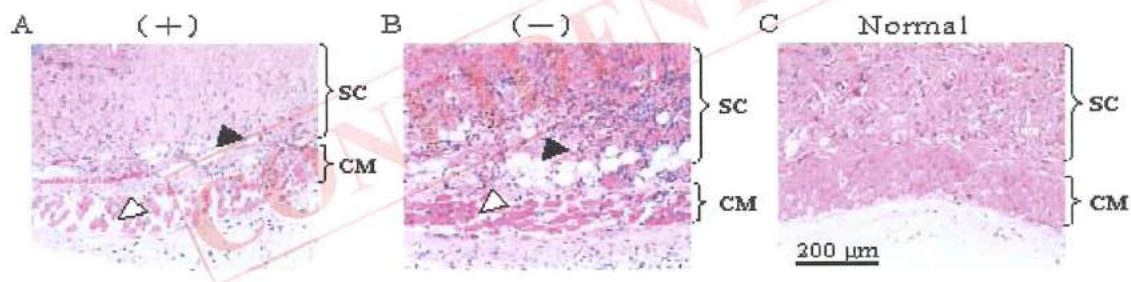
There were few inflammatory cells (mainly neutrophils) stained bluish purple with HE at the normal sites (Figure 3C) but many inflammatory cells in the ERI (+) and (-) specimens. However, inflammatory cell infiltration was more marked in the ERI (-) than in the ERI (+) specimen (Figures 3A and 3B), suggesting less severe wounding in the latter.

### 3.4. Blood vessels in subcutaneous tissue on day 3 after burn wound induction

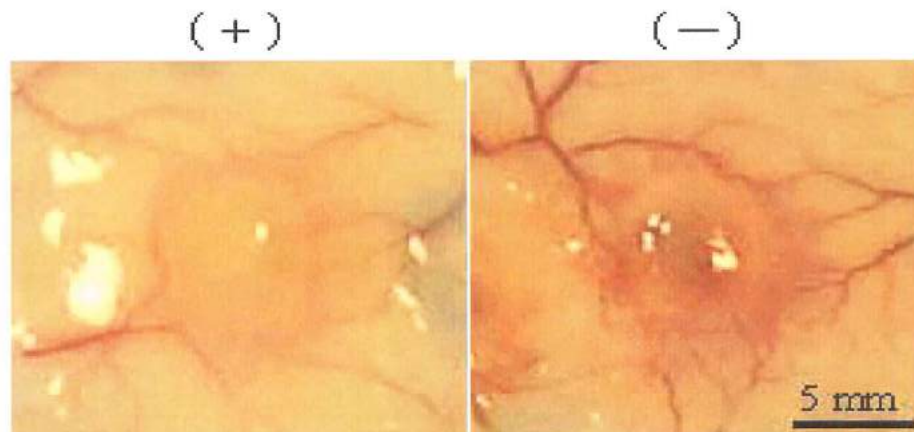
Capillaries near the wound were observed from the subcutaneous tissue side (Figure 4). There were more capillaries around the burn wound in the ERI (-) than in the ERI (+) specimen.

## 4. Discussion

To confirm burn wound healing after ERI application, we evaluated the effects of ERI application on the



**Figure 3.** Histological images of the skin after burn wound induction (day 3). All photograph are HE-stained cross-sectional images of the skin ( $\times 20$  magnification). (+): ERI lotion application (A), (-): PS lotion application (B), Normal site: (C). A and B: Burn wound site, C: Normal site. SC: Subcutaneous tissue, CM: Cutaneous muscle.  $\Delta$ : Parts not stained with HE in the SC,  $\blacktriangle$ : Parts not stained with HE in the CM.



**Figure 4.** Status of blood vessels observed from the subcutaneous tissue side on day 3 after burn wound induction. (+): ERI lotion application, (-): PS lotion application. The central area indicates the wound site.

wound surface. Initially, ERI was directly applied, but it dried immediately, and so a moist environment could not be maintained. Therefore, to maintain a moist environment on the wound surface, we evaluated the use of ERI ointments or dressings. However, to facilitate the observation of serial changes of the wound surface, a lotion was prepared using cmc-Na, which is transparent and viscous and has no pharmacological action. Cmc-Na, which is a polymer for pharmaceutical preparations also used for dressings, is freely soluble in water, viscous, and stable, and serves as a protective colloid, and, therefore, is often used as a dispersal agent or binder. In this experiment, the viscous lotion form was used to retain ERI at the burn wound site for a certain time and maintain its healing effects.

After injury, ERI or PS lotion was applied 3 times/day, and skin tissue in the mouse burn wound model was resected on day 3. For the histopathological examination of the effects of ERI, HE-stained specimens were prepared and observed by microscopy. In specimens after ERI or PS application, third degree burns were histologically observed, but a comparison of histological findings between the two specimens showed definite differences (Figure 4).

In the ERI (-) specimen after treatment with PS lotion as a control, the epidermis in the burn wound area disappeared, and the entire dermis including its residual appendages underwent coagulation-liquefaction necrosis. In addition, necrosis extended to the CM, and muscle fibers were atrophied. A large amount of nuclear disintegration substances (positive for hematoxylin) was sporadically observed (Figure 3B). The SC showed marked inflammatory reactions.

Histological examination of the specimen after treatment with ERI lotion showed coagulation necrosis from the epidermis at the burn wound site to the entire dermis. However, the necrosis was mild compared with the ERI (-) specimen, and the structure of muscle fibers was preserved without the progression of necrosis to liquefaction (Figure 3A). In the SC, nuclear disintegration substances (positive for hematoxylin) were sporadically observed, but inflammatory reactions were mild compared with the ERI (-) specimen.

From Figure 4, blood vessels from the subcutaneous tissue side to the area near the wound were confirmed. On day 3 after injury, capillaries could be confirmed at the site of injury and surrounding area in the ERI (-) specimen but were negligibly observed in the ERI (+) specimen. Considering the presence of a clearly smaller wound area in the ERI (+) than in the ERI (-) specimen on day 3 (Figure 1), this decrease in capillaries in the ERI (+) specimen suggests an early, smooth transition from the inflammation stage to granulation stage on day 3. Altavilla *et al.* reported that the presence of angiogenic factor in the injured area is closely associated with the process of wound healing. They

suggests that a defect in vascular endothelial growth factor (VEGF) regulation might be associated with wound-healing disorders (16). Alternatively, ERI may have a suppressive effect on angiogenesis based on the capillary decrease shown in Figure 4.

Thus, the effects of ERI lotion were evaluated in a mouse skin burn wound model. When the depth of burn wounds is similar among mice, ERI lotion applied to wounds reduces necrotic changes and inflammatory reactions occurring until day 3 after injury.

In general, the wound healing process consists of 3 stages, *i.e.*, inflammation, granulation, and reconstruction stages. Day 3 in this study corresponds to the inflammation stage, when cells such as neutrophils phagocytose injured cells and secrete physiologically active substances such as cytokines. In this study, inflammatory cell infiltration from the dermis to subcutaneous tissue was less pronounced in the ERI (+) than in the ERI (-) specimen, suggesting that ERI reduces inflammation (Figures 3A and 3B).

The burn wound healing process is complex, involving inflammatory aspects, such as cytokines, growth factors and proteases (17,18). Naito *et al.* reported that the beneficial effects of electrolyzed alkaline water (EAW) on aspirin-induced gastric mucosal injury may be attributed to its anti-inflammatory properties *via* inhibition of tumor necrosis factor- $\alpha$  (TNF- $\alpha$ ) expression (19). Therefore, we considered that ERI inhibits the expressions of factors such as TNF- $\alpha$ , VEGF and matrix metalloproteinases (MMPs). In the future, some additional research may elucidate the mechanism and role of this process.

Histological examination was performed in the inflammation stage until day 3 after injury but not in the granulation or reconstruction stage. In the future, we intend to study the effects of ERI in these stages. In addition, on the wound surface with a maintained moist environment and infection, the control of infection is important, and we also intend to evaluate dressings (such as hydrocolloids, hydropolymers, and alginate acid salts) using ERI with antimicrobial effects.

In this study, the effects of ERI on burn wounds were evaluated, and its wound healing-promoting effects were observed. Although further evaluation is necessary, the clinical application of ERI is expected.

## 5. Conclusion

We experimentally evaluated the healing effects of ERI on third degree burn wounds. The results of this study suggest that ERI is effective for improving burn wounds and promotes burn wound healing.

## Acknowledgements

The authors thank Ms. Mari Yamanaka for providing technical assistance in some parts of experimentation.

## References

1. Robbins SL, Angell M, Kumar V. Environmental Disease; Thermal Burns. In: Basic Pathology: 3rd edition (Robbins SL, Angell M, Kumar V, ed.), WB Saunders, Philadelphia, USA, 1981; pp. 247-249.
2. Williams WG. Pathophysiology of the burn wound. In: Total Burn Care, 2nd edition (Hemdon D, ed.), Saunders, London, UK, 2002; pp. 514-521.
3. Kujath P, Michelsen A. Wounds - from physiology to wound dressing. *Dtsch Arztebl Int.* 2008; 105:239-248.
4. Brett DW. A review of moisture-control dressings in wound care. *J Wound Ostomy Continence Nurs.* 2006; 33:3-8.
5. Akita S, Akino K, Imaizumi T, Hirano A. A basic fibroblast growth factor improved the quality of skin grafting in burn patient. *Burns.* 2005; 31:855-858.
6. Akita S, Akino K, Imaizumi T, Tanaka K, Anraku K, Yano H, Hirano A. The quality of pediatric burn scars is improved by early administration of basic fibroblast growth factor. *J Burn Care Res.* 2006; 27:333-338.
7. Akasaka Y, Ono I, Tominaga A, Ishikawa Y, Ito K, Suzuki T, Imaizumi R, Ishiguro S, Jimbow K, Ishii T. Basic fibroblast growth factor in an artificial dermis promotes apoptosis and inhibits expression of  $\alpha$ -smooth muscle actin, leading to reduction of wound contraction. *Wound Rep Reg.* 2007; 15:378-389.
8. Ono I, Akasaka Y, Kikuchi R, Sakemoto A, Kamiya T, Yamashita T, Jimbow K. Basic fibroblast growth factor reduces scar formation in acute incisional wounds. *Wound Rep Reg.* 2007; 15:617-623.
9. Okajima M. Abstract of Japanese society for applied research in negative ion. 2002.
10. Korematu A, Sugibayashi K, Okajima M, Ishii F. Preparation and stability of surfactant free emulsions using electrolyzed deoxidized and ionized water. *Mater Technol.* 2003; 21:273-285.
11. Kitamura T, Koike M, Todo H, Okajima M, Ishii F, Sugibayashi K. Preparation of surfactant-free emulsions using electrolyzed water and its regulation effect on the skin permeation of compounds. *Nippon Koshohin Gakkaishi.* 2008; 32:1-9.
12. Kitagawa T, Okajima M, Shimokawa K, Ishii F. Physicochemical properties of magnesium aluminum silicates (smectites<sup>®</sup>) gels prepared by electrolytic-reduction ion water. (1): rheological properties. *Mater Technol.* 2008; 26:50-54.
13. Okajima M, Shimokawa K, Ishii F. Physicochemical properties of magnesium aluminum silicate (smectone<sup>®</sup>) gels prepared using electrolytic-reduction ion water (2): Effects of various salts on the phase diagram. *Colloids Surf B Biointerfaces.* 2009; 72:284-288.
14. Papp A, Kiraly K, Härmä M, Lahtinen T, Uusaro A, Alhava E. The progression of burn depth in experimental burns: a histological and methodological study. *Burns.* 2004; 30:684-690.
15. Kaneko T, Hashimoto A, Umehara N, Tezuka M. Effects of a new wound dressing material SG-01 in an experimental rat skin burn and decubitus ulcer model. *J Health Sci.* 2006; 52:459-464.
16. Atavilla D, Saitta A, Cucinotta D, Galeano M, Deodato B, Colonna M, Torre V, Russo G, Sardella A, Urna G, Campo GM, Cavallari V, Squadrito G, Squadrito F. Inhibition of lipid peroxidation restores impaired vascular endothelial growth factor expression and stimulates wound healing and angiogenesis in the genetically diabetes mouse. *Diabetes.* 2001; 50:667-674.
17. Martin P. Wound healing: aiming for perfect skin regeneration. *Science.* 1997; 276:75-81.
18. Manuel JA, Gawronska-Kozak B. Matrix metalloproteinase 9 (MMP-9) is upregulated during scarless wound healing in athymic nude mice. *Matrix Biol.* 2006; 25:505-514.
19. Naito Y, Takagi T, Uchiyama K, Tomatsuri N, Matsuyama K, Fujii T, Yagi N, Yoshida N, Yoshikawa T. Chronic administration with electrolyzed alkaline water inhibits aspirin-induced gastric mucosal injury in rats through the inhibition of tumor necrosis factor- $\alpha$  expression. *J Clin Biochem Nutr.* 2002; 32:69-81.

(Received September 16, 2009; Revised October 20, 2009; Accepted October 24, 2009)